

## DELAYED EFFECTS OF NEONATAL EXPOSURE TO TWEEN 80 ON FEMALE REPRODUCTIVE ORGANS IN RATS

M. GAJDOVÁ\*, J. JAKUBOVSKÝ† and J. VÁLKY‡

\*Institute of Preventive and Clinical Medicine, Limbová 14, 833 01 Bratislava, †Institute of Pathologic Anatomy, Medical Faculty, Comenius University, and ‡Clinic of Gynaecology and Obstetrics, Teaching Hospital, Bratislava, Czechoslovakia

(Accepted 23 October 1992)

**Abstract**—Neonatal female rats were injected ip (0.1 ml/rat) with Tween 80 in 1, 5 or 10% aqueous solution on days 4–7 after birth. Treatment with Tween 80 accelerated maturation, prolonged the oestrus cycle, and induced persistent vaginal oestrus. The relative weight of the uterus and ovaries was decreased relative to the untreated controls. Squamous cell metaplasia of the epithelial lining of the uterus and cytological changes in the uterus were indicative of chronic oestrogenic stimulation. Ovaries were without corpora lutea, and had degenerative follicles.

### INTRODUCTION

While investigating the oestrogenous properties of the pesticide Fosmet administered to neonatal rats we found that a 10% emulsion concentrate of Tween 80 can increase the mean relative weight of the uterus and cause changes in the endometrium that are characteristic of the action of oestrogens (Gajdová *et al.*, 1988). In the rats exposed to Tween 80 we found a significant prolongation of the oestrous cycle and persistent vaginal oestrus in adulthood (Vargová *et al.*, 1990). Beside other findings, histological investigation also revealed planocellular metaplasia of the endometrial epithelium. Similar changes after the application of some substances with oestrogenous effect were described by Bulger and Kupfer (1985).

The results of the examination of the controls indicated that the oestrogenous effects that were observed may be caused by the presence of the emulsifier. We decided, therefore, to analyse in detail the possible oestrogenous effect of Tween 80. In order to do this, we observed the onset of vaginal opening and the length of the oestrous cycle, as well as its cytologic characterization, in rats treated neonatally with Tween 80. Female rat sexual organs were examined histologically.

### MATERIAL AND METHODS

**Tested substance.** Tween 80 (Merck, Schuchard, Germany) was prepared in 1, 5 and 10% aqueous solution. The compound is an oleic acid and polyethyleneglycol 300–monoanhydrosorbitether (Czecho-Slovak Pharmacopeia, 1987).

**Methods.** Mature rats were mated (two females to one male) and the female rats from the resultant litters were divided into five groups as follows:

group 1 (untreated control), eight rats were not given any substance; group 2 (negative control), 10 rats were given aqua pro injectione at a dose of 0.1 ml/rat and were killed after vaginal opening; group 3 (positive control), five rats were each injected with 50 µg Agostibén (Biotika, Slovenská Lupča, C-SFR; Agostibén (DES) is diethylstilboestrolum in oil helianthus, 15 mg in 1 ml); groups of six, five and six rats were injected with a 1, 5 or 10% aqueous solution of Tween 80, respectively, at a dose of 0.1 ml/rat. The rats were kept under controlled conditions, with a 12-hr light/dark cycle, and at 20–22°C and 50–60% relative humidity. Food and water were available *ad lib*.

The substances were administered ip on days 4, 5, 6 and 7 after birth. In the following days the onset of vaginal opening was observed. The oestrus cycle was examined at wk 10, 14 and 18 of life. Vaginal smears were obtained daily between 09.00 and 10.00 hr for 14 days: tap water at room temperature was introduced into the vagina using an eye dropper and the vaginal content was removed. One drop of the content was put on an ethanol-washed microscope slide, left to dry and fixed with methanol for 5 min. Staining was performed according to Pekárek (Luksch, 1953) and the slides were examined microscopically and classified as to the stage of the oestrous cycle according to the criteria of Allen (1922). At 5 months old, the rats were killed by cervical dislocation and the uterus, ovaries, adrenal glands and pituitary gland were removed. The organs were weighed and then fixed with 10% buffered formol, and embedded in paraffin. Sections from paraffin blocks were stained with haematoxylin and eosin.

**Statistical evaluation.** The data were analysed by Student's *t*-test and results were expressed as the mean  $\pm$  SEM.

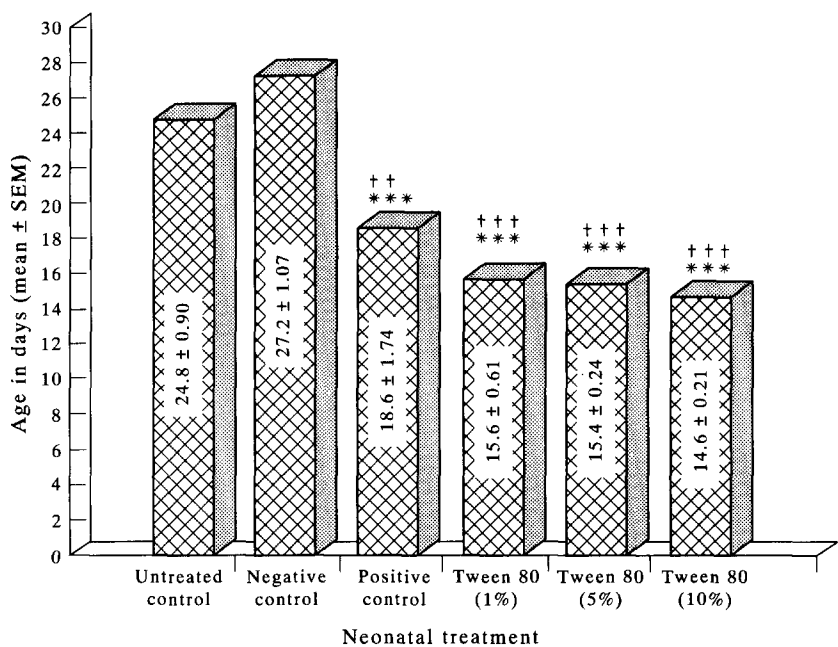


Fig. 1. Time of vaginal opening in female rats neonatally treated with Tween 80. Values marked with asterisks differ significantly (Student's *t*-test) from the corresponding value for untreated control (†††*P* ≤ 0.01; ††††*P* ≤ 0.001) or the negative control (\*\*\**P* ≤ 0.001).

RESULTS

None of the tested substances affected the growth and viability of neonatal female rats. A statistically significant (*P* < 0.01) decrease in body weight was found in adult rats that had been given 1% Tween 80 or DES in comparison with the untreated control. All of the rats that were treated with Tween 80 or DES had significantly advanced vaginal opening in comparison with the untreated and negative controls (Fig. 1). We found a statistically significant (*P* ≤ 0.0484) difference in the vaginal opening time between the groups given the medium and the highest Tween 80 dose. The average length of the oestrous cycle (Table 1) in the untreated control group throughout the whole test was 4.3 days, in the positive control group it was 9.4 days, and after Tween 80 administration it ranged from 9.3 to 14 days. Compared with the untreated and negative controls, this prolongation was statistically signifi-

cant (*P* ≤ 0.001). In the positive control and in all groups of rats that were given Tween 80 cytological investigation revealed a shortening of dioestrus and earlier onset of pro-oestrus, and the prolongation of the end of pro-oestrus and the beginning of meta-oestrus. In most rats the late phases of meta-oestrus were absent. In the group given the highest doses of Tween 80, examination of the ovaries at autopsy revealed multiple cavities of 3-mm diameter in three rats, and similar cavities were also found in two rats in the positive control group. Macroscopically, we found a smaller-sized uterus in one rat in the positive control group. In the group given the lowest dose of Tween 80, in two rats the uterus was enlarged and had a marked vascular pattern.

Increased relative weight of the adrenals was found in all groups, in comparison with the untreated control, although only in the 1% Tween 80 group was the increase statistically significant (*P* ≤ 0.05). In

Table 1. Mean length of the oestrus cycle in rats treated neonatally with Tween 80

Treatment	No. of rats	Mean length of oestrus cycle (days) in rats aged		
		10 wk	14 wk	18 wk
Untreated control	8	4.5 ± 0.14	4.0 ± 0.09	4.6 ± 2.44
Positive control	5	10.4 ± 1.47***	7.7 ± 0.71***	10.0 ± 0.75***
Tween 80: 1%	6	13.2	14.0	11.6
5%	5	9.3	9.6	8.8
10%	6	11.8	12.8	13.2
Tween treatments combined		11.6 ± 2.81***	12.3 ± 0.74***	11.2 ± 0.69***

Values are means ± SEM for the number of rats shown, and those marked with asterisks differ significantly (Student's *t*-test) from the corresponding value for the untreated control (\*\*\**P* < 0.001).

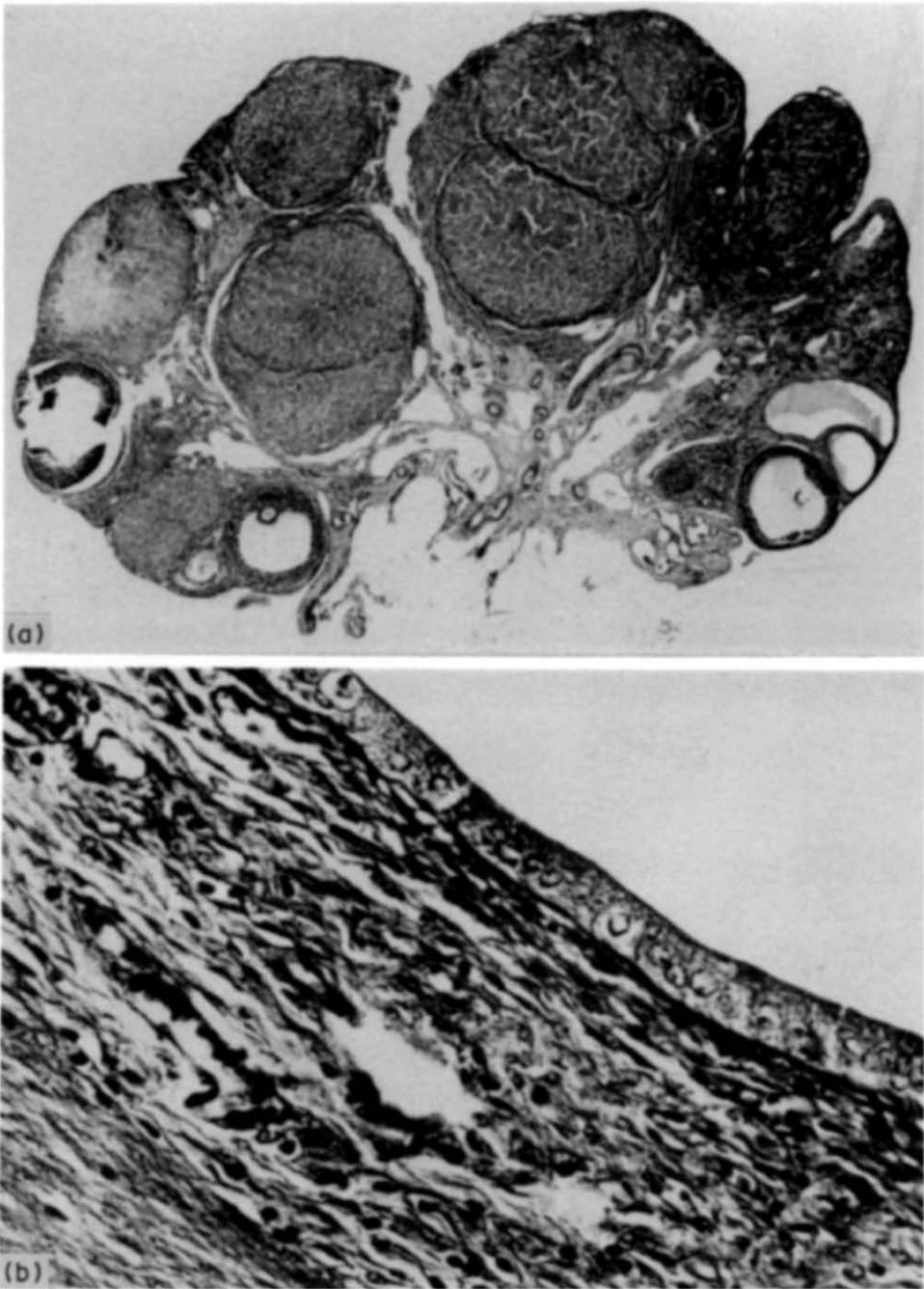


Plate 1. Untreated control. (a) Ovary with normal follicles and corpora lutea. Haematoxylin and eosin (HE)  $\times 40$ . (b) Cubic cells lining the uterus lumen. Their nuclei are in the same level. HE  $\times 400$ .

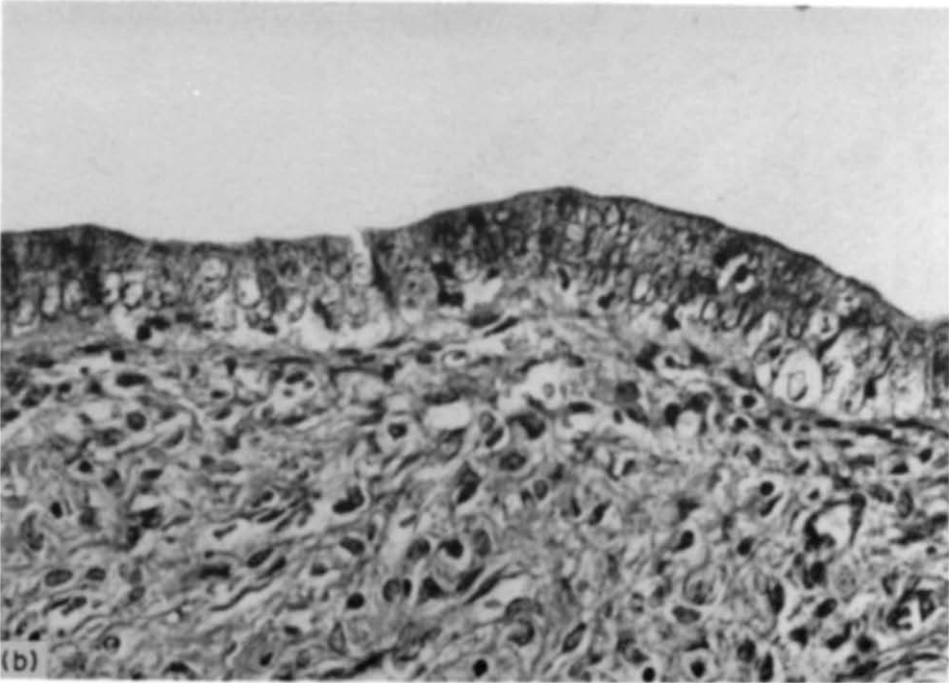
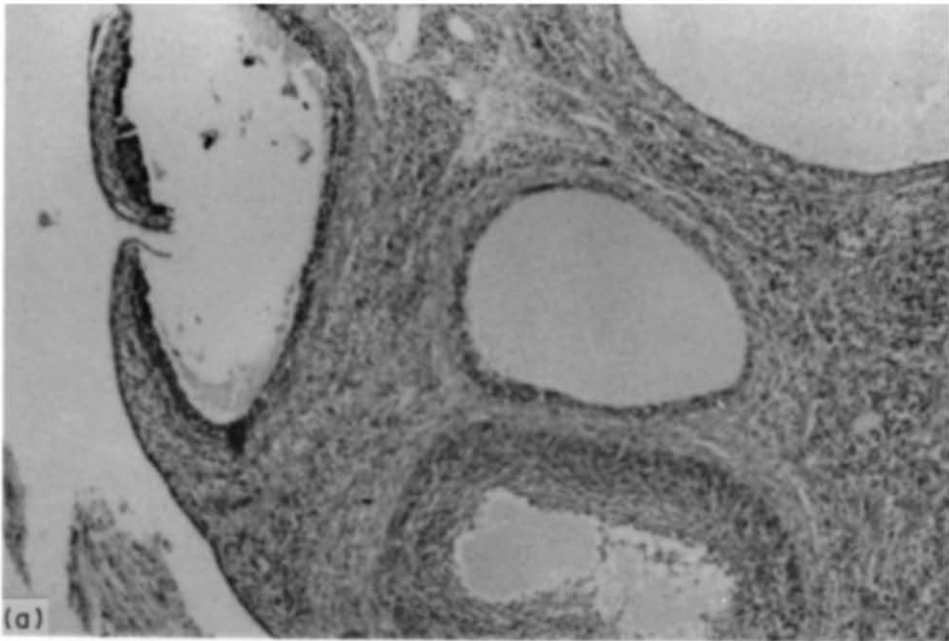


Plate 2. Positive control (DES). (a) Ovary with degeneratively changed follicles without corpora lutea. HE  $\times$  150. (b) Cylindrical cells lining the uterus lumen. Their nuclei are differently placed and cytoplasm is vacuolized. HE  $\times$  800.

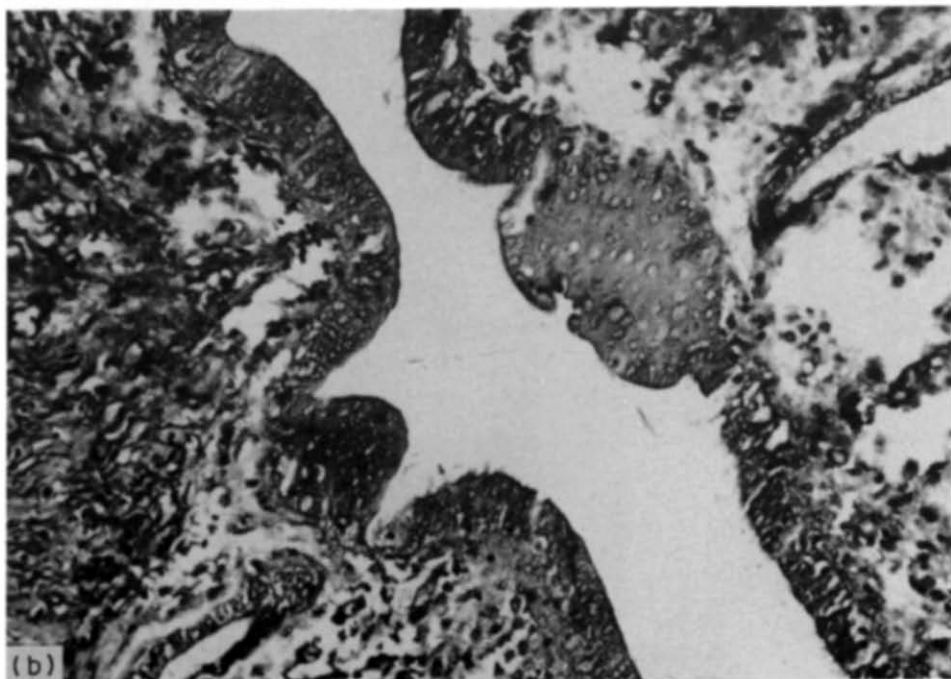
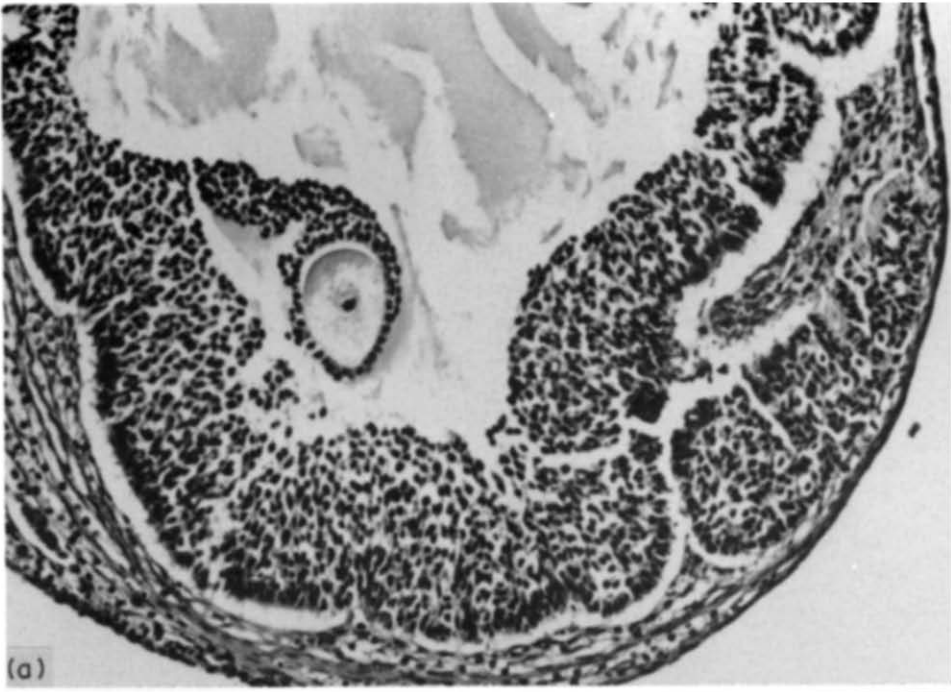


Plate 3. 10% Tween 80. (a) Ovary: degenerated follicle. HE  $\times$  400. (b) Uterus: cylindrical epithelium with nuclei placed in different levels (similar to Plate 2B). A planocellular metaplasia focus is also visible. HE  $\times$  400.



Table 2. Relative weights of organs of rats treated neonatally with Tween 80

Treatment	No. of rats	Body weight (g)	Relative weight (% of body weight) of				
			Adrenal glands	Ovaries	Uterus	Hypophysis	Thymus
Untreated control	8	348.1 ± 9.01	0.127 ± 0.0075	0.193 ± 0.0085	1.628 ± 0.191	0.038 ± 0.0026	0.988 ± 0.210
Positive control	5	280.0 ± 13.87**	0.132 ± 0.0090	0.164 ± 0.0260	0.861 ± 0.131*	0.049 ± 0.0026**	1.542 ± 0.240
Tween 80: 1%	6	315.0 ± 5.77**	0.152 ± 0.0053*	0.131 ± 0.0071***	1.592 ± 0.082	0.045 ± 0.0030	1.365 ± 0.150
5%	5	320.0 ± 11.40	0.132 ± 0.0090	0.122 ± 0.0089***	0.999 ± 0.147*	0.041 ± 0.0008	1.204 ± 0.091
10%	6	344.1 ± 12.47	0.139 ± 0.0093	0.136 ± 0.0073***	1.516 ± 0.101	0.141 ± 0.0041	1.175 ± 0.100

Values are means ± SEM for the number of rats shown, and those marked with asterisks differ significantly (Student's *t*-test) from the corresponding value for the untreated control (\*\**P* < 0.001).

all Tween-treated groups we found a statistically significant (*P* < 0.001) decrease in the relative weight of the ovaries in comparison with the untreated control (Table 2). In the positive control the decrease was not statistically significant. A significantly (*P* ≤ 0.05) decreased relative weight of the uterus was found only in the group given 5% Tween 80 and in the positive control group. No significant differences were observed in pituitary gland relative weights between rats treated with Tween 80 and untreated controls; however, the relative weights of pituitary glands in the positive controls were significantly (*P* ≤ 0.01) higher than those in the untreated controls.

Plates 1–3 show photomicrographs of ovaries and uteri from treated and untreated control rats. In the positive control (Plate 2) we found microscopically degenerated follicles in the ovaries with complete absence of corpora lutea. The epithelial cells of the uterus lumen lining were high, cylindrical, and their nuclei were differently placed with a low or medium amount of chromatin, sometimes with mitoses. In one case a planocellular metaplasia focus protruding into the cavum uteri was found. Findings in the ovaries, similar to those in the positive control group were also observed in all of the groups given Tween 80. The appearance of the epithelial cells of the lining of the uterus in all of the groups treated with Tween 80 was similar to that in the positive control, except that the cytoplasm of these cells was slightly darker. Planocellular metaplasia could be seen in the epithelium lining of the uterus lumen and in the endometrial glands in the group given 10% Tween 80. Vacuoles of the cylindrical epithelium lining of the uterus frequently contained fragments of dying cells resembling granulocytes. Light microscopic investigations failed to prove any significant changes in other organs.

#### DISCUSSION

Tween 80 is a classical non-ionic surface-active detergent. It is widely used as an additive in pharmaceuticals and in the food industry. Some of the Tweens are considered to be carcinogens or co-carcinogens (Lewis, 1979). Several of the stimulating properties of tweens are already known. For example

Tween 80 at appropriate concentrations in culture medium causes cell elongation of *Mycobacterium avium* (Masaki *et al.*, 1990) or stimulates the formation of intra-cellular membranous structures in micro-organisms.

In our study, we found that 4-day administration of Tween 80 to female rats during the period crucial for the development and function of reproductive organs accelerates the maturation of these organs. We found significant prolongation of the oestrous cycle and induction of persistent vaginal oestrus. The persistence of vaginal oestrus after the perinatal exposure of female rats to oestrogens used to be ascribed to oestrogens (Barraclough, 1961; Gorski, 1971). In the present study, significant reductions were observed in the relative weights of the uterus and ovaries. Gellert (1978) considered this phenomenon to result from the absence of corpora lutea. The decrease in the relative weight of the uterus following neonatal exposure to DES in rats was described by Medlock *et al.* (1988). In our study we found a significant decrease in body weight at the end of the trial in the group given the lowest dose of Tween 80 and in the positive control. The inhibitory effect of oestrogen on rat growth is known (Hart, 1990). This effect has been attributed to depressed function of the anterior pituitary related to inhibition of the hypophysial growth promoting factor. The most apparent histological finding was planocellular metaplasia of the endometrial epithelium of the uterus in the group given 10% Tween 80. The changes were in many ways similar to those resulting from the administration of DES to the positive controls, and identical to the changes seen in the uterus and ovaries after chronic endocrinal stimulation by oestrogens (Heywood and Wadsworth, 1980; Highman *et al.*, 1977).

**Acknowledgements**—The authors are grateful to Dr Ladislava Wsolova for her valuable help in statistical calculation, Daniela Bobriková and Dr Katarína Miháliková for technical assistance, and Dr M. Zöldy and Dr K. Kahayová for information services.

#### REFERENCES

- Allen E. (1922) The oestrous cycle of the mouse. *American Journal of Anatomy* **30**, 297–350.

- Barraclough C. A. (1961) Production of anovulatory, sterile rats by single injection of testosterone propionate. *Endocrinology* **68**, 62–67.
- Bulger W. H. and Kupfer D. (1985) Estrogenic activity of pesticides and xenobiotics on uterus and male reproductive tract. In *Endocrine Toxicology*. Edited by J. A. Thomas and K. S. Korach. pp. 1–33. Raven Press, New York.
- Gajdová M., Vargová M., Jakubovský J., Grunt J., Války J. and Galbavý Š. (1988) Estrogenic effects of fosmet on neonatal rat uterus. *Bratislavské Lekárske Listy* **89**, 843–847.
- Gellert R. J. (1978) Kepone, mirex, dieldrin and aldrin: estrogenic activity and the induction of persistent vaginal estrus and anovulation in rats following neonatal treatment. *Environmental Research* **16**, 131–138.
- Gorski R. A. (1971) Gonadal hormones and perinatal development of neuroendocrine function. In *Frontiers in Neuroendocrinology*. Edited by L. Martini and W. F. Ganong. pp. 237–290. Oxford University Press, New York.
- Hart J. E. (1990) Endocrine pathology of estrogens: species differences. *Pharmacology and Therapeutics* **47**, 203–218.
- Heywood R. and Wadsworth P. F. (1980) Experimental toxicology of estrogens. *Pharmacology and Therapeutics* **8**, 125–142.
- Highman B., Norwell M. J. and Schnellenberger T. E. (1977) Pathological changes in female C3H mice continuously fed diets containing diethylstilboestrol or 17 $\beta$  estradiol. *Journal of Environmental and Pathological Toxicology* **1**, 1–30.
- Lewis R. J., Sr (1979) *Registry of Toxic Effects of Chemical Substances*. 1978 Ed. DHEW/NIOSH Publ. No. 79–100. Cincinnati, OH.
- Luksch, F. (1953) Úvod do poševní cytologie. *Státní zdravotní nakladatelství* p. 27. (In Czech).
- Masaki S., Sugimori G., Okamoto A., Imose J. and Hayashi Y. (1990) Effect of Tween 80 on the growth of *Mycobacterium avium* complex. *Microbiology and Immunology* **43**, 653–663.
- Medlock K. L., Sheehan D. M., Nelson C. J. and Branham W. S. (1988) Effects of postnatal DES treatment on uterine growth, development, and estrogen receptor levels. *Journal of Steroid Biochemistry* **29**, 527–532.
- Vargová M. *et al.* (1990) Study of toxic and genotoxic effects of selected chemicals on the organism. Final Report on the Task State Plan of Technical Development N-05-535-863-03. pp. 62–89, Ú PKM, Bratislava.